



Dieulafoy Duodenal Ulceration: A Rare Cause of Massive Digestive Hemorrhage

S.Darhoua ^{a*}, A.Nadi ^b, O.Bahlaoui ^b, F.Belabbes ^a,
H.Delsa ^a, W.Khannoussi ^{a,b} and I.Ben El Barhdadi ^a

^a Department of Gastroenterology, Cheikh Khalifa Hospital, Morocco.

^b Department of Gastroenterology, Mohammed VI International University Hospital, Morocco.

Authors' contributions

This work was carried out in collaboration among all authors. All authors read and approved the final manuscript.

Article Information

DOI: <https://doi.org/10.9734/ajrrga/2025/v8i1156>

Open Peer Review History:

This journal follows the Advanced Open Peer Review policy. Identity of the Reviewers, Editor(s) and additional Reviewers, peer review comments, different versions of the manuscript, comments of the editors, etc are available here: <https://www.sdiarticle5.com/review-history/129343>

Case Report

Received: 03/11/2024

Accepted: 08/01/2025

Published: 13/01/2025

ABSTRACT

Dieulafoy ulceration (DU) is a rare cause of digestive hemorrhage. It usually occurs in the upper half of the stomach. Other duodenal, jejunal and even colonic localizations have been described, but are much rarer.

We report a case of duodenal Dieulafoy ulceration causing upper GI hemorrhage in a 74-year-old female patient, initially admitted to intensive care for melena with signs of hypovolemic shock. She had a history of non-valvular atrial fibrillation on DOAC, with no other antecedents. An oeso-gastro-duodenal fibroscopy was performed after hemodynamic stabilization and transfusion of 4 packed red blood cells, and showed active bleeding of duodenal origin from a punctiform ulceration at D3.

*Corresponding author: Email: sdarwa96@gmail.com;

Hemostasis was achieved by placement of a hemostatic clip with no immediate complications. The patient remained stable during hospitalization with no further deglobulisation; hemoglobin was stable at 9.1 g/dL. She was discharged after 7 days of hospitalization without complications. The patient was seen for a follow-up consultation, and showed no further recurrence of bleeding after 5 months. Dieulafoy ulceration is a particular form of duodenal ulcer confined to an artery of abnormal caliber, which can lead to cataclysmic hemorrhage. Endoscopic diagnosis can be very difficult, particularly in the first episode. The hemoclip has proved safe and effective in controlling bleeding due to Dieulafoy ulceration.

Keywords: Digestive hemorrhage; dieulafoy ulceration; melena.

1. INTRODUCTION

Dieulafoy ulceration (DU), an abnormal arterial lesion of the gastrointestinal tract, was first described by Gallard in 1884, then named after this French surgeon by George Dieulafoy in 1898 Lee et al. (2003). The particularity of this lesion lies in the existence of an abnormal vessel in the digestive submucosa, eroded by a mucosal micro ulceration. The latter, sometimes punctiform, can be difficult to identify, particularly in periods of haemorrhage, which explains the failures reported in the literature.

Duodenal localization of Dieulafoy ulceration is rare, as this condition mainly affects the stomach Chaussende et al. (2000).

Gastrointestinal endoscopy can be used to make the diagnosis in periods of haemorrhage, and to ensure haemostasis using thermal or mechanical methods (clips, elastic ligation). We report a case of Dieulafoy ulceration of duodenal location, revealed by massive upper digestive hemorrhage, diagnosed during oeso-gastro-duodenal fibroscopy. Characteristics of the

lesion, diagnostic circumstances and therapeutic means are discussed.

2. CLINICAL OBSERVATION

A 74-year-old woman was admitted to intensive care for melena with signs of hypovolemic shock. She had a history of non-valvular atrial fibrillation on DOAC, no other antecedents including no known digestive or extra-digestive neoplastic pathology, no history of surgery and no history of NSAID use. On admission, the patient was pale and tachycardic at 113 bpm, hypotensive at 77/56 mmHg, with a soft abdomen and blackish stool on rectal examination. Laboratory investigations revealed microcytic hypochromic anemia with hemoglobin 3.6 g/dl, platelet count 159,000/mm³, prothrombin 75.2%, and normal liver and renal function. Initial management consisted of vascular filling, transfusion and prescription of intravenous proton pump inhibitors. After discussion with the cardiologist and analysis of the patient's risk-benefit ratio, we decided to discontinue the DOAC and start her on low-molecular-weight heparin 0.4 iu x2/d.

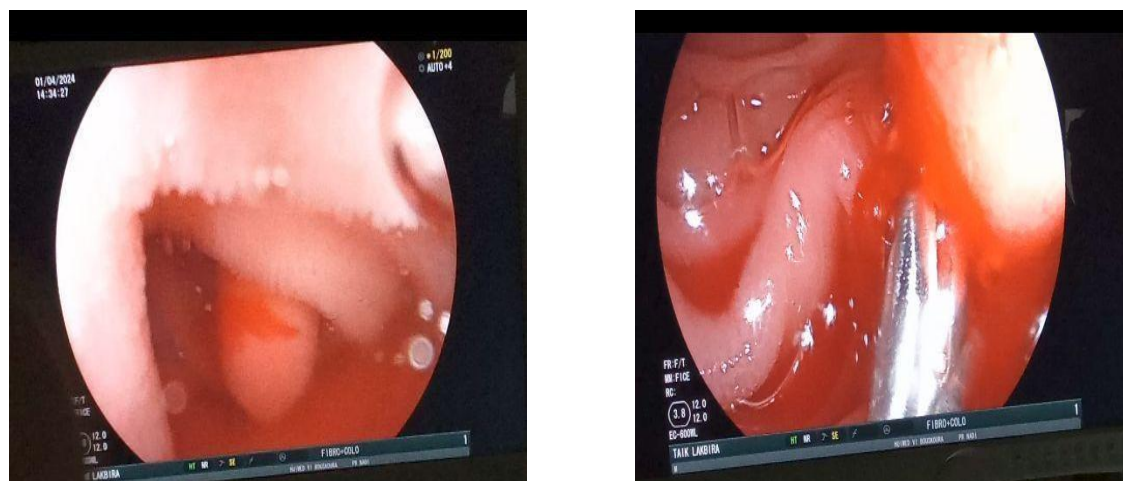


Fig. 1. Bleeding in Dieulafoy's lesion from the duodenal. A: Spurting blood, B: Bleeding stopped after hemoclip hemostasis

An oeso-gastro-duodenal fibroscopy was performed after hemodynamic stabilization and transfusion of 4 packed red blood cells, and showed active bleeding of duodenal origin from a punctiform ulceration at D3. Hemostasis was achieved by placement of a hemostatic clip with no immediate complications. Typical bleeding from duodenal ulceration and hemostasis after hemocliping are shown in Fig. 1. The patient remained stable during hospitalization without further deglobulisation; hemoglobin was stable at 9.1 g/dL. She was discharged after 7 days of hospitalization without complications. The patient was seen for a follow-up consultation, and showed no further recurrence of bleeding after 5 months.

3. DISCUSSION

Dieulafoy ulceration (DU) is a loss of substance that destroys the muscularis mucosae and erodes a fairly voluminous artery without an arterial lesion, but following an ectopic and sinuous superficial course. Around 2% of upper GI haemorrhages are associated with UD Vreeburg et al. (1997). It usually occurs in male subjects over 60 with significant comorbidities, including cardiovascular disease, respiratory disease, chronic renal failure, liver cirrhosis and neurological disease, all of which influence blood coagulation Ding et al. (2010).

The pathophysiology of these vascular anomalies leading to mucosal ischemia and subsequent erosion remains incompletely understood. Some authors suggest that spontaneous bleeding highlights the potential role of oxidative and ischemic stress, triggered by a variety of factors, such as NSAID use, alcohol consumption, chronic gastritis and previous surgery, all of which may contribute to vessel rupture. Another theory suggests that arterial thrombosis is the cause of ischemia and

bleeding. Despite its uncertain pathogenesis, it appears that vascular lesions are more common in the elderly or those with more underlying diseases Nojkov and Cappell (2015).

Digestive endoscopy is the gold standard for the diagnosis of this lesion, in the presence of jet bleeding, the visualization of a vessel or the existence of a platelet plug on a mucosal erosion or even normal, non-ulcerated mucosa Jeon and Kim (2015), but endoscopic diagnosis can be difficult in cases of massive hemorrhage, and due to the small size of the lesion. Eventually, endoscopic ultrasound (EUS) has also been used to aid endoscopic diagnosis by revealing a tortuous submucosal vessel close to the mucosal defect Carvalho et al. (2012).

Endoscopic treatment is currently advocated as a first-line choice for UD homeostasis. A wide variety of hemostasis techniques, including epinephrine or sclerosant injection, heating probe or argon coagulation, elastic ligation, hemoclip or a combination of these methods, have been used for hemostasis of Dieulafoy ulceration with permanent hemostasis achieved in over 90% of patients Lee et al. (2003). Each technique has advantages and disadvantages linked to the haemostatic mechanism involved, the technical procedure itself and variable success rates Chung et al. (2000) (Table 1).

A review of the published literature on the application of endoscopic hemoclips in 106 patients and the application of ligature in 80 patients as monotherapy for Dieulafoy hemorrhagic lesions reveals that both techniques are almost uniformly effective in achieving initial hemostasis, and both techniques have a low rate of rebleeding, typically 10% Dulic-Lakovic et al. (2011). They are particularly effective in the hands of experts with extensive experience of these techniques.

Table 1. Advantages and disadvantages of endoscopic techniques for Dieulafoy lesions

	Advantages	Disadvantages
Epinephrine injection	Simple Low cost	Risk of rebleeding
Hemoclip	Low risk of rebleeding Efficient	Inaccessible lesion
Ligature	Low risk of rebleeding Easy	Risk of perforation
Plasma Argon	Simple	Superficial coagulation only
Coagulation APC		(inaccessible to larger, deeper vessels)

In our case, there was no hemorrhagic recurrence at follow-up, demonstrating that the hemoclip remains an easy and safe method for controlling recurrent bleeding. Surgery is the last option for patients with uncontrolled recurrent bleeding or an unidentified bleeding site. Thanks to advances in endoscopy, UD detection rates have increased, leading to a reduction in the mortality rate for UD-related bleeding from 80% to 8.6% Baxter and Aly (2010).

Furthermore, with regard to anticoagulant management in GI bleeding, the best therapeutic options are based on the availability of DOAC antagonist agents, which should be used in cases of life-threatening acute GI bleeding, which remains rare in practice Picard and Camus (2021). However, it is not advisable to follow up with LMWH or UFH during DOAC therapy, as this increases the risk of bleeding events Periendoscopic management of direct oral anticoagulants (2024).

4. CONCLUSION

Dieulafoy ulceration is a particular form of duodenal ulcer confined to an artery of abnormal caliber, which can lead to cataclysmic hemorrhage. Endoscopic diagnosis can be very difficult, particularly in the first episode.

The hemoclip has proved safe and effective in controlling bleeding due to Dieulafoy ulceration. Endoscopic hemostasis should be tried as a first-line treatment, with surgery reserved for those who fail.

DISCLAIMER (ARTIFICIAL INTELLIGENCE)

Author(s) hereby declare that NO generative AI technologies such as Large Language Models (ChatGPT, COPILOT, etc) and text-to-image generators have been used during writing or editing of this manuscript.

COMPETING INTERESTS

Authors have declared that no competing interests exist.

RÉFÉRENCES

Baxter, M., & Aly, E. (2010). Dieulafoy's lesion: Current trends in diagnosis and management. *Annals of the Royal*

College of Surgeons of England, 92(7), 548-554.

Carvalho, R., Almeida, N., Ferreira, M., Amaro, P., Bernardes, A., Cipriano, M. A., et al. (2012). An unusual endoscopic image of a submucosal angiodysplasia. *Case Reports in Gastrointestinal Medicine*, 2012, e186065.

Chaussende, C., Collet, D., Laurent, C., Monguillon, M., & Masson, B. (2000). Dieulafoy duodenal ulceration: About two observations. *Annales de Chirurgie*, 125(1), 66-67.

Chung, I. K., Kim, E. J., Lee, M. S., Kim, H. S., Park, S. H., Lee, M. H., et al. (2000). Bleeding Dieulafoy's lesions and the choice of endoscopic method: Comparing the hemostatic efficacy of mechanical and injection methods. *Gastrointestinal Endoscopy*, 52(6), 721-724.

Ding, Y. J., Zhao, L., Liu, J., & Luo, H. S. (2010). Clinical and endoscopic analysis of gastric Dieulafoy's lesion. *World Journal of Gastroenterology*, 16(5), 631-635.

Dulic-Lakovic, E., Dulic, M., Hubner, D., Fuchssteiner, H., Pachofszky, T., Stadler, B., et al. (2011). Bleeding Dieulafoy lesions of the small bowel: A systematic study on the epidemiology and efficacy of enteroscopic treatment. *Gastrointestinal Endoscopy*, 74(3), 573-580.

Jeon, H. K., & Kim, G. H. (2015). Endoscopic management of Dieulafoy's lesion. *Clinical Endoscopy*, 48(2), 112-120.

Lee, Y. T., Walmsley, R. S., Leong, R. W. L., & Sung, J. J. Y. (2003). Dieulafoy's injury. *Gastrointestinal Endoscopy*, 58(2), 236-243.

Nojkov, B., & Cappell, M. S. (2015). Gastrointestinal bleeding from Dieulafoy's lesion: Clinical presentation, endoscopic findings, and endoscopic therapy. *World Journal of Gastrointestinal Endoscopy*, 7(4), 295-307.

Periendoscopic management of direct oral anticoagulants: A prospective cohort study. (2024). *Gut*, 68(6), 969. Available at: <https://gut.bmj.com/content/68/6/969>

Picard, F., & Camus, M. (2021). Management of antiplatelet agents and anticoagulants during digestive hemorrhage: The cross-cutting view of the cardiologist and hepatogastroenterologist. *Medical Press Form*, 2(5), 522-531.

Vreeburg, E. M., Snel, P., De Bruijne, J. W., Bartelsman, J. F. W. M., Rauws, E. A. J., & Tytgat, G. N. J. (1997). Acute upper gastrointestinal bleeding in the Amsterdam area: Incidence, diagnosis, and clinical

outcome. *American Journal of Gastroenterology*, 92, 236. Available at: <https://openurl.ebsco.com/contentitem/gcd:16017318?sid=ebsco:plink:crawler&id=ebsco:gcd:16017318>

Disclaimer/Publisher's Note: The statements, opinions and data contained in all publications are solely those of the individual author(s) and contributor(s) and not of the publisher and/or the editor(s). This publisher and/or the editor(s) disclaim responsibility for any injury to people or property resulting from any ideas, methods, instructions or products referred to in the content.

© Copyright (2025): Author(s). The licensee is the journal publisher. This is an Open Access article distributed under the terms of the Creative Commons Attribution License (<http://creativecommons.org/licenses/by/4.0>), which permits unrestricted use, distribution, and reproduction in any medium, provided the original work is properly cited.

Peer-review history:

The peer review history for this paper can be accessed here:

<https://www.sdiarticle5.com/review-history/129343>